



# Footpad Dermatitis in Poultry: A Common Issue in Commercial and Backyard Flocks

*Authored by Leonie Jacobs, Associate Professor, School of Animal Sciences, Virginia Tech*

## Introduction

Footpad dermatitis refers to a lesion on the footpad and/or toes, characterized by black, necrotic skin and inflammation. Necrosis is often preceded by thickening of the outer layer of skin, a condition called hyperkeratosis. Footpad dermatitis is a common type of contact dermatitis in poultry, where feet are inflamed and show corrosive lesions or ulcers on pads and/or toes. Footpad dermatitis lesions often have a black appearance, because of cell necrosis (cell death). These lesions can be superficial or deep.

These lesions are an animal welfare problem because they are painful, depending on the severity of the lesions. They can also affect production outcomes, because birds will be less motivated to walk to feed and water. Extreme cases will result in behavioral restriction.

Once a lesion has developed, the bird is at risk of secondary infection, as the barrier of the skin is compromised. Examples are *E. coli* or salmonella infections.

## Footpad Dermatitis Occurs Frequently

Footpad dermatitis is very common in both the poultry industry and in backyard flocks, although numbers for the latter are not available. Some examples of findings in commercial birds are as follows:

**Broiler chickens:** In southeastern U.S., about 50% of commercial (or heavy) broiler chickens were found with some degree of footpad dermatitis (Opengart et al. 2018). In Europe, a Danish study found 58% of commercial broilers with lesions on their feet (Lund et al. 2017).

**Laying hens:** A study examining nearly 300 cage-free laying hen flocks found on average 40% of hens in each flock affected by footpad dermatitis (Niebuhr et al. 2009). An experimental study showed footpad dermatitis to be a common issue in both furnished cages and cage-free birds, with prevalences ranging between 60% and 93% of the birds having a lesion (Weitzenbürger et al. 2006).

**Turkeys:** As with other poultry, footpad dermatitis can be a common occurrence. Nearly 50% of young turkeys showed lesions on their feet in one study (Bergmann et al. 2013), and another reported the lesions in 95% of turkeys from 41 flocks in North Carolina (Da Costa et al. 2014).

## Scoring Footpad Lesions Using a Categorical Scale

Severity of footpad dermatitis lesions can be quantified using a scoring system (fig. 1). Regularly assess a representative sample of your flock (all birds in the case of a small flock, or 50 birds in the case of a large flock) to keep an eye on the progress.

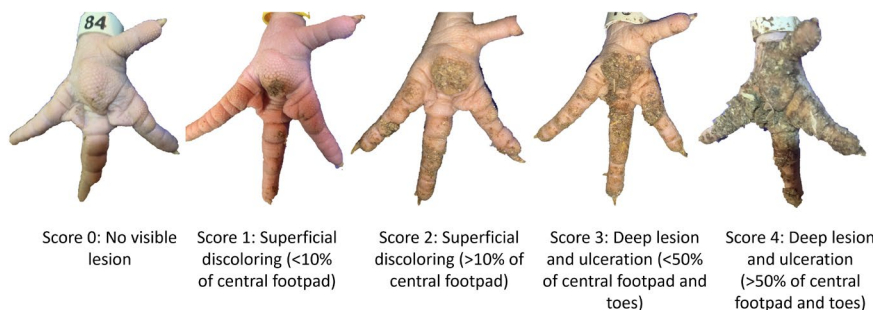


Figure 1. Example of a categorical scale to quantify footpad dermatitis severity in poultry, with higher scores representing worse lesions (Welfare Quality Network 2009). (Photo courtesy of Leonie Jacobs.)

# How Does Footpad Dermatitis Develop?

The major risk factor for footpad dermatitis is the quality of litter or bedding. The key issues are wet litter and associated chemicals present in the wet litter (for instance, ammonia). Litter type and depth also play a role. Other factors — such as body weight, diet, leaky waterers, and ventilation — can indirectly impact prevalence and severity of lesions (fig. 2). For instance, poor ventilation can lead to wet bedding material, and prolonged contact with wet bedding can induce lesion development (fig. 3).

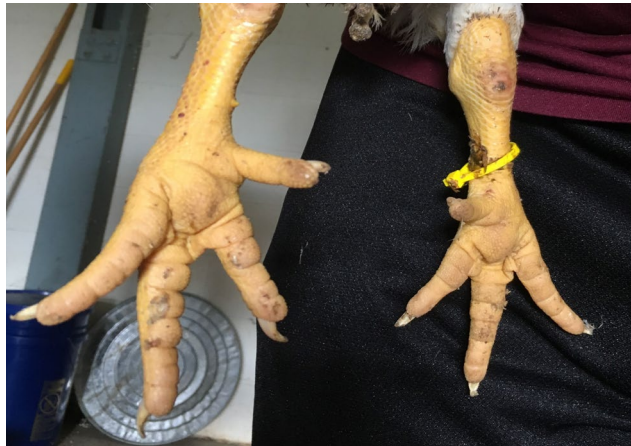

Figure 2. Example of healthy footpads in a broiler chicken. (Photo courtesy of Leonie Jacobs.)

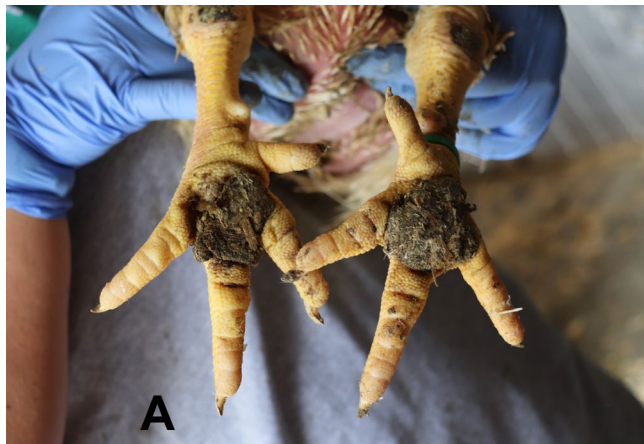
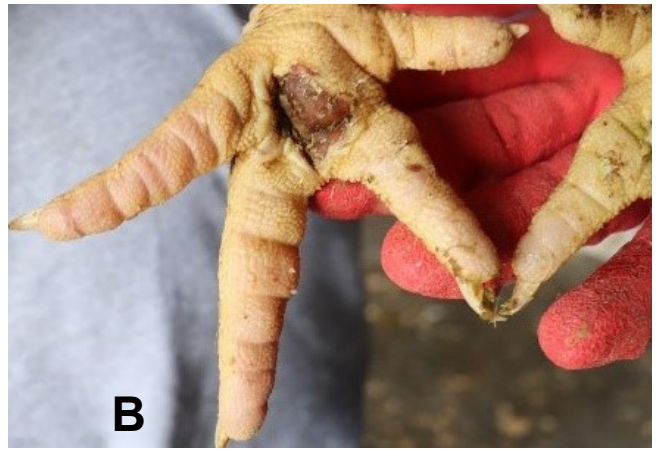
Figure 3. Examples (A and B) of severe footpad lesions in a broiler chicken. Feet may appear dirty, but debris is “attached” to the large lesion. Moderate and severe lesions can be painful. (Photos courtesy of Leonie Jacobs.)



## What Can You Do?

Preventing is better than remedying lesions after they have developed. A key strategy is to manage the litter moisture and associated chemicals. Litter and drinker management play important roles in preventing these issues. Yet, there are some options to heal lesions or reduce the prevalence of footpad dermatitis:

- Consult a veterinarian to treat the lesions appropriately.
- Gently clean and wrap the lesion so that the feet are no longer in direct contact with litter or other bedding materials. Replace the bandage frequently.
- Ensure the environment (bedding, litter) is dry by replacing the litter or topdressing with an absorbent material, such as pine shavings (Freeman et al., 2020).

## What Not To Do

There are some videos online that show backyard flock owners performing DIY surgeries on their birds to remove inflamed lesions. This is inhumane. Although they may not show it, poultry can experience pain, and home surgeries will cause severe pain and distress. Surgeries can be done by a licensed veterinarian, if it is deemed necessary.

## Additional Resources

Poultry Extension Collaborative. 2020. “Footpad Dermatitis in Poultry: A Common Issue in Commercial and Backyard Flocks.” Poultry Press. <https://www.canva.com/design/DAEOE7CvsVo/dXQ4wKnk-Nxs-MG33bs7uw/view>

## References

- Bergmann, S., N. Ziegler, T. Bartels, J. Hübel, C. Schumacher, E. Rauch, S. Brandl, A. Bender, G. Casalicchio, M-E Krautwald-Jughanns, and M. H. Erhard. 2013. "Prevalence and Severity of Foot Pad Alterations in German Turkey Poult During the Early Rearing Phase." *Poultry Science* 92: 1171-76.
- Da Costa, M. J., J. L. Grimes, E. O. Oviedo-Rondón, I. Barasch, C. Evans, M. Dalmagro, and J. Nixon. 2014. "Footpad Dermatitis Severity on Turkey Flocks and Correlations with Locomotion, Litter Conditions, and Body Weight at Market Age." *Journal of Applied Poultry Research* 23, no. 2: 268-79.
- Freeman, N., F. A. M. Tuytens, A. Johnson, V. Marshall, A. Garmyn, L. Jacobs. 2020. "Remedying Contact Dermatitis in Broiler Chickens with Novel Flooring Treatments." *Animals* 10, no. 10: 1761.
- Lund, P. V., L. R. Nielsen, A. R. S. Oliveira, and J. P. Christensen. 2017. "Evaluation of the Danish Footpad Lesion Surveillance in Conventional and Organic Broilers: Misclassification of Scoring." *Poultry Science* 96, no. 7: 2018-28.
- Niebuhr, C., C. Arhant, A. Lugmair, B. Gruber, and K. Zaludik. 2009. "Foot Pad Dermatitis in Laying Hens Kept in Non-cage Systems in Austria." Abstract. [https://www.cabi.org/Uploads/animal-science/worlds-poultry-science-association/WPSA-italy-2009/6\\_welfare2009\\_niebuhr.pdf](https://www.cabi.org/Uploads/animal-science/worlds-poultry-science-association/WPSA-italy-2009/6_welfare2009_niebuhr.pdf).
- Opengart, K., S. F. Bilgili, G. L. Warren, K. T. Baker, J. D. Moore, and S. Dougherty. 2018. "Incidence, Severity, and Relationship of Broiler Footpad Lesions and Gait Scores of Market-Age Broilers Raised Under Commercial Conditions in the Southeastern United States." *Journal of Applied Poultry Research*. 27: 424-32. <https://doi.org/10.3382/japr/pfy002>.
- Weitzenbürger, D., A. Vits, H. Hamann, M. Hewicker-Trautwein, and O. Distl. 2006. "Macroscopic and Histopathological Alterations of Foot Pads of Laying Hens Kept in Small Group Housing Systems and Furnished Cages." *British Poultry Science* 47, no. 5: 533-43.
- Welfare Quality Network. 2009. "Welfare Assessment Protocol for Poultry." *ASG Veehouderij B.V.*: Lelystad, the Netherlands. [http://www.welfarequality.net/media/1019/poultry\\_protocol.pdf](http://www.welfarequality.net/media/1019/poultry_protocol.pdf).

**Scan to access more publications about poultry.**



<http://bit.ly/41AqRFT>

---

Visit our website: [www.ext.vt.edu](http://www.ext.vt.edu)

Produced by Virginia Cooperative Extension, Virginia Tech, 2023

Virginia Cooperative Extension is a partnership of Virginia Tech, Virginia State University, the U.S. Department of Agriculture, and local governments. Its programs and employment are open to all, regardless of age, color, disability, gender, gender identity, gender expression, national origin, political affiliation, race, religion, sexual orientation, genetic information, military status, or any other basis protected by law.

VT/0923/APSC-191P